Opportunities to students for midcourse improvement of performance through specific interventions

Inderprastha Dental College & Hospital

Date Sheets of three internal assessment examinations in a given academic year

Inderprastha Dental College & Hospital

46/1, Site-IV, Industrial Area, Sahibabad,
Ghaziabad-201010 (U.P.)

1st INTERNAL EXAMINATION DATE SHEET
1st yr BDS (R)

Theory

SL NO	DATE	DAY	SUBJECT	BATCH	Time
1.	08.06.2021	Tuesday	Human Anatomy	A B C D E	10.00am to 1pm
2.	10.06.2021	Thursday	Physiology & Biochemistry	A B C D E	10.00am to 1pm
3.	12.06.2021	Saturday	Dental Anatomy & Dental Histology	A B C D E	10.00am to 1pm

Batches: A: 1-20, B: 21-40, C:41-60, D: 61-80, E: 81 onwards (as per the S.No. mentioned in the list)

Dr.Rahul Paul
(Principal)

Inderprastha Dental College & Hospital Principal Sahibabad

Inderprastha Dental College & Hospital

46/1, Site-IV, Industrial Area, Sahibabad,
Ghaziabad-201010 (U.P.)

2nd INTERNAL EXAMINATION DATE SHEET

1st YEAR BDS (R)
No. of students:100

LT- 3 (1-50)
LT- 4 (51 onwards)

DATE:17.09.2021
Time:-09.00am 12.00pm

Theory

SL NO	DATE& DAY	SUBJECT
1.	04.10.2021 Monday	Human Anatomy
2.	06.10.2021 Wednesday	Physiology & Biochemistry
3.	08.10.2021 Friday	DADH

Practical **Time:-08:30 am Onwards**

SL NO	DATE & DAY	SUBJECT	BATCH
1	18.10.2021 Monday	Physiology Biochemistry	A B
2	19.10.2021 Tuesday	Human Anatomy DADH	A C
3	20.10.2021 Wednesday	Human Anatomy DADH	B A
4	21.10.2021 Thursday	Physiology Biochemistry	C A
5	22.10.2021 Friday	Human Anatomy DADH	C B
6	23.10.2021 Saturday	Physiology Biochemistry	B C

Batches: A: 1-33,
B: 34-67,
C: 68 onwards

Dr.Rahul Paul
(Principal)

Inderprastha Dental College & Hospital * Principal * Sahibabad

Inderprastha Dental College & Hospital

46/1, Site-IV, Industrial Area, Sahibabad,
Ghaziabad-201010 (U.P.)

THIRD INTERNAL EXAMINATION DATE SHEET

1st YEAR BDS (R)

LT- 3 (1-50)
LT- 4 (51 onwards)

DATE:25.11.2021

Theory

SL NO	DATE& DAY	SUBJECT
1.	13.12.2021 Monday	Human Anatomy
2.	15.12.2021 Wednesday	Physiology & Biochemistry
3.	17.12.2021 Friday	DADH

Practical

SL NO	DATE & DAY	SUBJECT	BATCH
1	06.12.2021 Monday	Physiology Biochemistry	A B
2	07.12.2021 Tuesday	Human Anatomy DADH	A C
3	08.12.2021 Wednesday	Human Anatomy DADH	B A
4	09.12.2021 Thursday	Physiology Biochemistry	C A
5	10.12.2021 Friday	Human Anatomy DADH	C B
6	11.12.2021 Saturday	Physiology Biochemistry	B C

Batches: A: 1-33,
B: 34-67,
C: 68 onwards

Dr.Rahul Paul
(Principal)

Inderprastha Dental College & Hospital Principal Sahibabad

Inderprastha Dental College & Hospital

Answer Sheet

Inderprastha Dental College & Hospital

Name of Examination ....1st Internal....

Course : BDS/Year....3rd Year....

Subject ...Oral pathology.... Paper ..... Part I/II

Theory / Practical ....Theory....

Name of Candidate .[redacted]

Roll No. ....[redacted]

Date & Time of Exam ....13-12-21....

Signature of Candidate ....[redacted]

Signature of the Invigilator ....13/12/21....

Signature of Examiner ..... Total Marks ....31....

Sect A.

(1) Ans. Premalignant lesion - It is defined as a benign, morphologically altered tissue that has a greater than normal risk of malignant transformation.

eg:- Leukoplakia, Erythroplakia, Nicotina stomatitis.

Premalignant cond^n:- defined as a genuz state associated with significant ↑zed risk of cancer eg OSMF.

Leukoplakia -

Leuko - white

Plakia - patch.

- Defined as white patch or plaque that cannot be characterized clinically or pathologically or any other disease.

Etiopathogenesis -

Some extrinsic local factor + Some intrinsic

1) Tobacoo -

Smokeless form :-

Tobacoo chewing

Tobacoo containing dentifices.

Snuff dipping.

Smoked form.

Bidis, cigarettes, pipes, Hookkas, chilum.

2) Alcohol

- irritating to the mucosa.

3) Chronic irritation -

Trauma, malocclusion, ill fitting denture, sharp tooth or restoration, hot & spicy food may irritate mucosa.

4) Syphilis.

5) Vit deficiency.

VitA - sq. metaplasia & keratinization of certain epithelial including gland & resp. mucosa

6) Homones - M & Female sex hormones do have some keratogenic effect.

7) Galvanism.

Inderprastha Dental College & Hospital

Name of Examination: 1st internal

Course : BDS/Year: 3rd Year

Subject: Paper: Part I/ II

Theory / Practical: Theory

Name of Candidate: [redacted]

Roll No.: [redacted]

Date & Time of Exam: 13-12-21

Signature of Candidate: [redacted]

Signature of the Invigilator: 13/12/21

Signature of Examiner: Total Marks:

Q3) Any

ii) Bruxism :-

- It is a habitual grinding or clenching of teeth, either during sleep or an unconcious habit during waking hours.

· Ethology -

1) Local factor :
2) Systemic factors
   - GIT disturbances, subclinical deficiencies.

3) Psychological factors.
   High stress, anxiety, emotion.

fear, rage, rejection:

4] Occupational factors

Athletes develop bruxism.
watchmaker.

5) Voluntary bruxism -
Chewing gum, tobacco, objects such as tooth picks or pencils.

CF -

1) typical grinding.
2) clinching motion.
3) effect on dentition.
4) effect on periodontium.
5) effect on masticatory muscles.
6) effect on TMJ.
7) head ache.
8) Psychologic & behavioural effects.
9) hypertrophy of the masticatory muscles, particularly masseter muscles.
10) causes bismus.

Inderprastha Dental College & Hospital

Evaluation is done at the End of Posting

Inderprastha Dental College & Hospital
46/1, Site-IV, Industrial Area, Sahibabad,
Ghaziabad-201010 (U.P.)

Department of Conservative Dentistry & Endodontics

U.G .Section

31/10/22 - 15/11/22

Batch E

END POSTING

DATE: 7/11/22

S.NO	Roll No	Name	Case History (10)	Clinical Quota (20)	Project/Seminar (10)	VIVA (10)	Total (50)
1	186089022	Ayman H	6	12	5	5	28
2	186089023	Bhavya A	6	13	6	6	30
3	186089025	Cedric B	5	9	6	5	25
4	186089030	Disha A	5	10	6	5	27
5	186089033	Drishti J	6	12	6	6	30
6	186089034	Ekta	6	11	6	6	29
7	186089035	Yamna V	5	12	7	7	30

Inderprastha Dental College & Hospital Sahibabad

CONSERVATIVE DENTISTRY & ENDODONTICS

Inderprastha Dental College & Hospital
46/1, Site-IV, Industrial Area, Sahibabad,
Ghaziabad-201010 (U.P.)

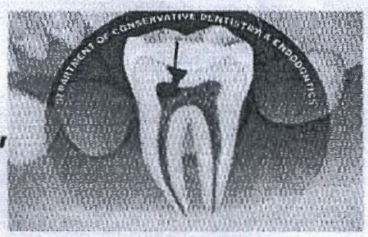

Department of Conservative Dentistry & Endodontics

U.G .Section

31/10/22 – 15/11/22.

Batch: E Mid Posting Viva Date: 7/11/22

S.NO	Name	VIVA (10)
1	Ayman Hassan	6
2	Bhavya Arora	7
3	Cedric Byoming	5
4	Disha Arora	6.
5	Drishti Jindal	5
6	Ekta	5
7	Garima Vaish.	6

Inderprastha Dental College & Hospital Sahibabad

> 5-Acceptable

< 5-Needs Improvement

CONSERVATIVE DENTISTRY & ENDODONTICS IPDC

Mock Examination of Post Graduate Students

Inderprastha Dental College & Hospital

Department of Orthodontics & Dentofacial Orthopedics

Practical mock examination

Batch 2018 DATE: 20/5/21

Name of postgraduate student	Myofunctional Case History & Bite Registration (25)	Bonding and wire fabrication (25)	Case 01 Presentation (10)	Case 02 Presentation (10)	Case 03 Presentation (10)	Case 04 Presentation (10)	Case 05 Presentation (10)	Total (100)
Archana Sen	17	18	7	7	6	8	6	69
Jyoti Mishra	13	15	6	5	6	6	5	56

Dr Rahul Paul
Principal, Professor & HOD
Department of Orthodontics

Inderprastha Dental College & Hospital Principal Sahibabad

Inderprastha Dental College & Hospital

Department of Orthodontics & Dentofacial Orthopedics

Theory mock examination

Batch 2018 DATE: 20/05/21

Name of postgraduate student	PAPER II (100)	PAPER III (100)	PAPER IV (100)	Total Marks (300)	Marks Obtained	Remarks (Minimum 150 marks required)
Archana Sen	65	61	68	300	194	Passed
Jyoti Mishra	50	52	56	300	158	Passed

Dr Rahul Paul
Principal, Professor & HOD
Department of Orthodontics

Inderprastha Dental College & Hospital
Principal
Sahibabad

Dental College & Hospital
46/1, Site-IV, Industrial Area, Sahibabad,
Ghaziabad-201010 (U.P.)

Internal Examination
Date Sheet
08.04.2021
Batch 2018

Internal Examination of 3rd year Post graduate students will be conducted in 1st week of May in 2021. Theory and Practical exam will be conducted as per university guidelines.

S.no.	Exam	Date	Time
1.	Paper II Theory	11.05.2021	9.00 am to 12.00pm
2.	Paper III Theory	12.05.2021	9.00 am to 12.00pm
3.	Paper IV Theory	13.05.2021	9.00 am to 12.00pm
4.	Practical	17.05.2021	8.30am onwards

It is mandatory for all students to appear for exams.

Theory exam will be conducted in LT-2 and practical will be held in respective department.

Dr. Rahul Paul
(Principal)
Cc.: Secretary & Jt. Secretary
C.E.O
All PG Departments
Accounts

Inderprastha Dental College & Hospital
Principal
Sahibabad

Continuous Performance Assessment Report

Inderprastha Dental College & Hospital
46/1, Site-IV, Industrial Area, Sahibabad,
Ghaziabad-201010 (U.P.)

CONTINUOUS PERFORMANCE ASSESSMENT REPORT

3rd B.D.S

Name of the student: [redacted] Roll No. [redacted] Year: 2019-21

First Term

Date: 28/12/20

S.No.	Criteria		Grade		
			General Medicine	General Surgery	Oral Pathology
1	Performance in class	Theory	2	2	1
		Practicals/Clinics	2	2	1
2	Record Book	Practicals/Clinics	2	2	1
3	Assignments		1	1	1
4	Punctuality		2	1	1
5	Behaviour		2	2	1

Subjects	Remarks	Signature of Faculty	Signature of Student
Gen. Medicine	Can do better	Vineet	[signature]
Gen.Surgery	Scope for improvement	[signature]	[signature]
Oral Pathology	Good! Keep it up	[signature]	[signature]

Second Term

Date: 30/12/20

S.No.	Criteria		Grade		
			Gen. Medicine	Gen.Surgery	Oral Pathology
1	Performance in class	Theory	2	2	1
		Practicals/Clinics	2	1	1
2	Record Book	Practicals/Clinics	2	1	1
3	Assignments.		1	1	1
4	Punctuality		1	1	1
5	Behaviour		2	1	1

Subjects	Remarks	Signature of Faculty	Signature of Student
Gen. Medicine	Very good	[signature]	[signature]
Gen.Surgery	Very good	[signature]	[signature]
Oral Pathology	well done!	[signature]	[signature]

Third Term

Date: 22/1/21

S.No.	Criteria		Grade		
			Gen. Medicine	Gen.Surgery	Oral Pathology
1	Performance in class	Theory	2	2	1
		Practicals/Clinics	2	1	1
2	Record Book	Practicals/Clinics	2	1	1
3	Assignments		1	1	1
4	Punctuality		1	1	1
5	Behaviour		2	1	1

Inderprastha Dental College & Hospital Sahibabad

Subjects	Remarks	Signature of Faculty	Signature of Student
Gen. Medicine	Very good	Ashok.	[signature]
Gen.Surgery	Excellent	[signature]	[signature]
Oral Pathology	Keep it up!	[signature]	[signature]

Grades: 1- Very Good 2- Good 3- Average 4- Below Average

Inderprastha Dental College & Hospital
46/1, Site-IV, Industrial Area, Sahibabad,
Ghaziabad-201010 (U.P.)

CONTINUOUS PERFORMANCE ASSESSMENT REPORT

2nd B.D.S

Name of the student: [redacted] Roll [redacted] Year: Dec-20- Feb22

First Term Date: 24.6.21

S.No.	Criteria		Grade					
			Pathology	Microbiology	Pharmacology	PCP	PCC	DM
1	Performance in class	Theory	2	3	3	3	3	4
		Practicals/Clinics	2	2	2	4	4	4
2	Record Book	Practicals/Clinics	2	2	2	4	2	2
3	Assignments		2	2	3	3	4	3
4	Punctuality		1	2	2	2	4	3
5	Behaviour		2	2	2	4	4	4

Subjects	Remarks	Signature of Faculty	Signature of Student
Pathology		KM	Grusha
Microbiology		SK	Grusha
Pharmacology		Abid	Grusha
PCP	Need to focus.	[illegible]	Grusha
PCC	work hard.	[illegible]	Grusha
DM	Scope for improvement.	[illegible]	Grusha

Second Term Date: 4.11.21

S.No.	Criteria		Grade					
			Pathology	Microbiology	Pharmacology	PCP	PCC	DM
1	Performance in class	Theory	2	2	3	2	3	2
		Practicals/Clinics	2	2	2	2	4	3
2	Record Book	Practicals/Clinics	1	3	1	1	2	2
3	Assignments		2	2	3	2	4	2
4	Punctuality		1	2	1	2	2	2
5	Behaviour		2	3	1	3	3	2

Subjects	Remarks	Signature of Faculty	Signature of Student
Pathology		Shyla	Grusha
Microbiology		Sonal	Grusha
Pharmacology		Abid	Grusha
PCP	Can do better.	Rizwi	Grusha
PCC		[illegible]	Grusha
DM			Grusha

Third Term Date: 23.12.21

S.No.	Criteria		Grade					
			Pathology	Microbiology	Pharmacology	PCP	PCC	DM
1	Performance in class	Theory	2	2	2	2	2	2
		Practicals/Clinics	2	2	2	2	2	1
2	Record Book	Practicals/Clinics	3	2	1	1	2	1
3	Assignments		2	2	2	2	2	2
4	Punctuality		1	1	1	2	1	2
5	Behaviour		2	2	1	2	2	2

Subjects	Remarks	Signature of Faculty	Signature of Student
Pathology		KM	Grusha
Microbiology		SK	Grusha
Pharmacology		[illegible]	Grusha
PCP	Scope for improvement.	[illegible]	Grusha
PCC		[illegible]	Grusha
DM	work hard.	Sandeep	Grusha

Grades: 1- Very Good 2- Good 3- Average 4- Below Average

Evaluation of Lab Work

CAVITY PREPARATION ON PLASTER MODEL

CAVITY	GRADE	SIGNATURE
CLASS I WAX-UP & CARVING		
① conventional on mandibular 1st molar	B	21/3/22
② conventional on maxillary 1st molar.	B	28/4/22
③ conservative on maxillary 1st molar.	B	21/5/22
CLASS I WITH BUCCAL / LINGUAL EXTENSION WAX-UP & CARVING		
① conservative with palatal extension on maxillary 1st molar.	B	21/5/22
② conservative with buccal extension on mandibular 1st molar.	B	28/4/22

Indraprastha Dental College & Hospital Principal Sahibabad

Inderprastha Dental College & Hospital

Evaluation of Clinical Cases

DAILY WORK DONE

S. No.	Date of Commencement	Date of Completion	O.P.D. No.	Sex	Age	Work Done	Grade	Signature of the Teacher in charge
6.	2/12/22	3/12/22	221232659	F	24.	Full mouth scaling done.	B	
7.	2/12/22	3/12/22	221232646	M	26	Full mouth scaling done	B	
8.	29/10/22	7/12/22	221029077	F	47	Full mouth Scaling done	B	
9.	6/12/22	8/12/22.	221131530	M	47	Full mouth scaling done	B	
10.								

Inderprastha Dental College & Hospital ★ Sahibabad
Principal

Evaluation of Journal Clubs

JC-4

CHECK LIST- 1

EVALUATION OF JOURNAL REVIEW PRESENTATIONS

Name of the Student: Dr.Teisovinuo Kesiezie Date: 17/11/2022

Topic: Etiology of maxillary canine impaction: a review

S. No.	Items for Observations During Presentation	Poor 0	Below Average 1	Average 2	Good 3	Very Good 4
1.	Article chosen was					✓
2.	Extent of understanding of scope & objectives of the paper by the candidate.					✓
3	Whether cross – reference have been consulted.			✓		
4	Whether other relevant publications consulted			✓		
5	Ability to respond to question on the paper / subject.				✓	
6	Audio- visual aids used.				✓	
7	Ability to defend the paper.				✓	
8	Clarity of presentation				✓	
9	Any other observation					
Total Score						24/32

Indraprastha Dental College & Hospital Ghaziabad Principal

17/11/22

Signature of Staff

Signature of HOD

Professor & Head
Department of Orthodontics
& Dentofacial Orthopaedics

Inderprastha Dental College & Hospital

Evaluation of Seminars

CHECK LIST- 2

EVALUATION OF SEMINAR PRESENTATIONS

Name of the Student: Dr. Prakher Saini **Date:** 5/11/2022
Topic: Digital Cephalometry

S. No.	Items for Observations During Presentation	Poor 0	Below Average 1	Average 2	Good 3	Very Good 4
1.	Whether other relevant publications consulted.				✓	
2.	Whether cross-references have been consulted.				✓	
3	Completeness of preparation				✓	
4	Clarity of presentation					✓
5	Understanding of subject				✓	
6	Ability to answer the question				✓	
7	Time schedule				✓	
8	Appropriate use of audio visual aids.				✓	
9	Any other observation					
					Total Score	25/32

Signature of Staff

Inderprastha Dental College & Hospital Principal Sahibabad

Signature of HOD

Professor & Head
Department of Orthodontics
& Dentofacial Orthopaedics

Evaluation of Clinico-Pathological Conference

Inderprastha Dental College & Hospital

46/1, Site-IV, Industrial Area, Sahibabad, Ghaziabad-201010 (U.P.)

CLINIC-PATHOLOGICAL CONFERENCE PRESENTATION

Date: 23/11/22

Venue: LT 1

Time: 10:00 AM

Topic: Modified Impression Technique For Flabby Ridges.

Name of the Presenter: Dr. Divya Kaushik

Signature	Signature	Signature
Department of Oral Pathology	Department of Oral Medicine	Department of Prosthodontics

Inderprastha Dental College & Hospital * Principal * Sahibabad

Inderprastha Dental College & Hospital

46/1, Site-IV, Industrial Area, Sahibabad,
Ghaziabad-201010 (U.P.)

CHECKLIST FOR EVALUATION OF CLINIC-PATHOLOGICAL CONFERENCE PRESENTATION

Name of PG: Dr. Divya Kaushik

Topic: Modified Impression Technique for flabby ridges

S.No	Items of observation during presentation	Poor 0	Below Average 1	Average 2	Good 3	Very Good 4
1	Completeness of history				✓	
2	Clarity of presentation				✓	
3	Logical order				✓	
4	Mentioned all positive and negative findings				✓	
5	Diagnosis: Whether it follows logically from history and findings				✓	
6	Investigations required				✓	
8	Interpretation of Investigations including histopathological evaluation				✓	
9	Ability to react to questioning logically, from history & findings				✓	
10	Ability to justify differential diagnosis				✓	
11	Treatment Planning				✓	
12	Total Score				✓	

Dr. Ish K. Sharma
Dept of Orthodontics

Signature of Evaluator

Inderprastha Dental College & Hospital Principal Sahibabad

Signature of Principal

Inderprastha Dental College & Hospital

46/1, Site-IV, Industrial Area, Sahibabad,
Ghaziabad-201010 (U.P.)

CHECKLIST FOR EVALUATION OF CLINIC-PATHOLOGICAL CONFERENCE PRESENTATION

Name of PG: Dr. Divya Kanshik

Topic: Mod. Impression Techniques for Flabby Ridges.

S.No	Items of observation during presentation	Poor 0	Below Average 1	Average 2	Good 3	Very Good 4
1	Completeness of history				✓	
2	Clarity of presentation				✓	
3	Logical order				✓	
4	Mentioned all positive and negative findings			✓		
5	Diagnosis: Whether it follows logically from history and findings				✓	
6	Investigations required				✓	
8	Interpretation of Investigations including histopathological evaluation				✓	
9	Ability to react to questioning logically, from history & findings				✓	
10	Ability to justify differential diagnosis				✓	
11	Treatment Planning				✓	
12	Total Score					

Signature of Evaluator

Inderprastha Dental College & Hospital Principal Sahibabad

Signature of Principal

Inderprastha Dental College & Hospital

46/1, Site-IV, Industrial Area, Sahibabad,
Ghaziabad-201010 (U.P.)

CHECKLIST FOR EVALUATION OF CLINIC-PATHOLOGICAL CONFERENCE PRESENTATION

Name of PG: Dr. Divya Kaushik

Topic: Modified Impression Technique for flabby ridges

S.No	Items of observation during presentation	Poor 0	Below Average 1	Average 2	Good 3	Very Good 4
1	Completeness of history					✓
2	Clarity of presentation					✓
3	Logical order				✓	
4	Mentioned all positive and negative findings				✓	
5	Diagnosis: Whether it follows logically from history and findings					✓
6	Investigations required					✓
8	Interpretation of Investigations including histopathological evaluation				✓	
9	Ability to react to questioning logically, from history & findings					✓
10	Ability to justify differential diagnosis				✓	
11	Treatment Planning					✓
12	Total Score					✓

Signature of Evaluator

23/11/22

Out of 0.5

Inderprastha Dental College & Hospital Principal Sahibabad

Signature of Principal

Inderprastha Dental College & Hospital

46/1, Site-IV, Industrial Area, Sahibabad,
Ghaziabad-201010 (U.P.)

CHECKLIST FOR EVALUATION OF CLINIC-PATHOLOGICAL CONFERENCE PRESENTATION

Name of PG: Dr. Divya Kaushik

Topic: Modified Impression technique for flabby ridges

S.No	Items of observation during presentation	Poor 0	Below Average 1	Average 2	Good 3	Very Good 4
1	Completeness of history			✓		
2	Clarity of presentation			✓		
3	Logical order			✓		
4	Mentioned all positive and negative findings			✓		
5	Diagnosis: Whether it follows logically from history and findings			✓		
6	Investigations required			✓		
8	Interpretation of Investigations including histopathological evaluation			✓		
9	Ability to react to questioning logically, from history & findings			✓		
10	Ability to justify differential diagnosis			✓		
11	Treatment Planning			✓		
12	Total Score					

Signature of Evaluator

Signature of Principal

Inderprastha Dental College Principal Sahibabad

Inderprastha Dental College & Hospital

46/1, Site-IV, Industrial Area, Sahibabad,
Ghaziabad-201010 (U.P.)

CHECKLIST FOR EVALUATION OF CLINIC-PATHOLOGICAL CONFERENCE PRESENTATION

Name of PG: Dr. Divya Kaushik

Topic: Modified Impression technique for flabby ridges

S.No	Items of observation during presentation	Poor 0	Below Average 1	Average 2	Good 3	Very Good 4
1	Completeness of history			✓		
2	Clarity of presentation			✓		
3	Logical order			✓		
4	Mentioned all positive and negative findings			✓		
5	Diagnosis: Whether it follows logically from history and findings			✓		
6	Investigations required			✓		
8	Interpretation of Investigations including histopathological evaluation			✓		
9	Ability to react to questioning logically, from history & findings		✓			
10	Ability to justify differential diagnosis			✓		
11	Treatment Planning			✓		
12	Total Score					

Signature of Evaluator

Dr. Nidhi Sharma
Deptt. of Cons.

Inderprastha Dental College & Hospital Principal Sahibabad

Signature of Principal

Inderprastha Dental College & Hospital

46/1, Site-IV, Industrial Area, Sahibabad,
Ghaziabad-201010 (U.P.)

CHECKLIST FOR EVALUATION OF CLINIC-PATHOLOGICAL CONFERENCE PRESENTATION

Name of PG: Dr. Divya Kaushik

Topic: Modified Impression technique for flabby ridges

S.No	Items of observation during presentation	Poor 0	Below Average 1	Average 2	Good 3	Very Good 4
1	Completeness of history				✓	
2	Clarity of presentation			✓		
3	Logical order			✓		
4	Mentioned all positive and negative findings			✓		
5	Diagnosis: Whether it follows logically from history and findings				✓	
6	Investigations required			✓		
8	Interpretation of Investigations including histopathological evaluation			✓		
9	Ability to react to questioning logically, from history & findings			✓		
10	Ability to justify differential diagnosis				✓	
11	Treatment Planning			✓		
12	Total Score					

Signature of Evaluator

Inderprastha Dental College & Hospital * Sahibabad * Principal

Signature of Principal

Inderprastha Dental College & Hospital

46/1, Site-IV, Industrial Area, Sahibabad,
Ghaziabad-201010 (U.P.)

CHECKLIST FOR EVALUATION OF CLINIC-PATHOLOGICAL CONFERENCE PRESENTATION

Name of PG: Dr. Divya Kaushik

Topic: Modified Impression Technique for flabby ridges

S.No	Items of observation during presentation	Poor 0	Below Average 1	Average 2	Good 3	Very Good 4
1	Completeness of history				✓	
2	Clarity of presentation				✓	
3	Logical order				✓	
4	Mentioned all positive and negative findings					
5	Diagnosis: Whether it follows logically from history and findings				✓	
6	Investigations required				✓	
8	Interpretation of Investigations including histopathological evaluation				✓	
9	Ability to react to questioning logically, from history & findings				✓	
10	Ability to justify differential diagnosis				✓	
11	Treatment Planning				✓	
12	Total Score				✓	

Inderprastha Dental College & Hospital Principal Sahibabad

Signature of Evaluator
Dr Trisha Rastogi
(Deptt of OMR)

Signature of Principal

Inderprastha Dental College & Hospital

46/1, Site-IV, Industrial Area, Sahibabad, Ghaziabad-201010
(U.P.)

CHECKLIST FOR EVALUATION OF CLINIC-PATHOLOGICAL CONFERENCE PRESENTATION

Name of PG: Dr. Divya Kaushik

Topic: Modified Impression Technique for flabby ridges.

S.No	Items of observation during presentation	Poor 0	Below Average 1	Average 2	Good 3	Very Good 4
1	Completeness of history					✓
2	Clarity of presentation					✓
3	Logical order					✓
4	Mentioned all positive and negative findings					✓
5	Diagnosis: Whether it follows logically from history and findings					✓
6	Investigations required					✓
8	Interpretation of Investigations including histopathological evaluation				✓	
9	Ability to react to questioning logically, from history & findings					✓
10	Ability to justify differential diagnosis					✓
11	Treatment Planning					✓

Inderprastha Dental College & Hospital Sahibabad

12	Total Score					

Signature of Evaluator

Signature of Principal

(Dept of Prosthodontics)

Uderprastha Dental College & Hospital
Principal
Sahibabad

MCQ’s

MCQ in orthodontics diagnosis

1. All of the following are essential diagnostic Aids except:

A. Periapical radiographs

B. Wrist x-rays

C. master study casts

D. Facial photographs

2. A patient suffering from epilepsy needs an orthodontic treatment. The dentist should:

A may the orthodontic treatment until epilepsy is in control

B. Proceed With an orthodontic treatment

C. Advise him that an epileptic patient cannot undergo an orthodontic treatment

D. None of the above

3. A boy undergoing orthodontic treatment takes aspirin. This results orthodontic tooth movement to be:

A. Faster than normal

B. Same as normal

C. Slower than normal

D. Cannot be predicted

4. Skeletal indicators of maturity are determined by:

A. Chest X-ray

B. Periapical X-ray

C. Hand wrist X-ray

D. Occlusal X-ray

E. Combination of B and C

Inderprastha Dental College & Hospital
Principal
Sahibabad

5. Brachycephalic individuals usually have:

A. Narrow dental arches

B. Broad dental arches

C. Normal dental arches

D. Both A & B

6. The molar relationship in a person with a concave profile is most likely to be:

A. Class I molar relationship

B. Class II division I molar relationship

C. Class III division II molar relationship

D. Class III molar relationship

7. Ideally, when the teeth are in normal occlusion the mandibular skeletal base as compared to the maxillary skeletal base is:

A. 2 to 3 mm anterior

B. 2 to 3 mm posterior

C 6 to 5 mm anterior

D. 5 to 6 mm posterior

8. When the mandibular plane and the Frankfort horizontal plane meet beyond the occipital region, it indicates:

A- Horizontal growing face

B. Vertical growing face

C High angle face

D. None of the above

Indraprastha Dental College & Hospital
Principal
Sahibabad

9. Deep mento-labial sulcus is seen in:

A. Class I malocclusion

B. Class II, division malocclusion

C Class I malocclusion with bimaxillary protrusion

D. Class Ill malocclusion

10. 'blanch test' is used to identify:

A. Incompetent lips

B. Deviated nasal septum

C. A shift in the mandible during closing

D. Abnormal frenal attachment

11. In Gnathostatic models the base of the maxillary cast is trimmed 80 that it is parallel to:

A. Frankfort horizontal plane

B. S-N plane

C Basion —Nasion plane

D. Bolton's plane

12. The diagnostic setup was first proposed by:

A. Calvin case

B. Edward Angle

C. H D Kesling

D. William Conrad

13. Backward path of mandibular closure is seen is

a) Class II division 2

b) Class I

c) Pseudo class III

d) Class III

Jaipur Prastha Dental College & Hospital
Principal
Sahibabad

14. Convex profile is seen in

a) Class I

b) Class II

c) Class III

d) None of above

15. Which of the following statements about the hand Wrist radiographs is incorrect:

A. It helps not only in assessing the growth of an individual, but also helps to predict future skeletal maturation rate and status

B. It is based upon the fact that the numerous small bones of hand, like carpals, metacarpals, etc show a predictable and scheduled pattern of appearance, ossification and union from birth to maturity.

C. It gives us a general idea regarding the amount and direction of growth

D. It helps in determination of skeletal maturity status prior to treatment of skeletal malocclusion such as skeletal class II Or class III malocclusion.

16. In orthodontic study models the bases of the maxillary and the mandibular casts are:

A. Parallel to each other

B. At 90 to each other

C At 300 to each other

D. At 1100 to each other

17. Which of the following methods is least accurate in determining the site of new bone deposition in laboratory animals:

A. Implants

B. Radiographs

C Tetracycline stains

D. Histochernical stains

Indraprastha Dental College & Hospital
Principal
Sahibabad

18. The lip is supported by

a) Relation of lip edge and facial surfaces of teeth

b) Labial sulcus between teeth and lip

c) Relationship of tongue and teeth

d) None

19. Normal nasolabial angle

a) 80°

b) 90-110°

c) 70°

d) 140°

20. Hyperactive mentalis activity is seen in

a) Class I

b) Class II division 1

c) Class II division 2

d) Class III

Indraprastha Dental College & Hospital
Principal
Sahibabad

Inderprastha Dental College & Hospital

Assignments

[redacted]

Enamel Lamellae

Enamel lamellae are thin, leaf like structures that extend from the enamel surface to the DEJ. Enamel lamellae extend for varying in depths from surface of enamel and consists of linear, longitudinally oriented defects filled with organic material with little mineral content.

It can be seen in transverse section.

- It can be seen in decalcified section because of protein content
- It is formed as a result of local failure of maturation process
- It may arise developmentally due to incomplete maturation of groups of prisms (in which case they would contain protein) or after eruption as cracks during function (containing saliva and oral debris.)

→ 3 types

Type A: Lamellae composed of poorly calcified rod segments. (restricted to enamel)
Type B: Lamellae consisting of degenerated cells (may extend to dentin)
Type C: Lamellae arising in erupted teeth where the cracks are filled with organic matter, presumeing originating from saliva. (may extended into dentin)

- Enamel lamellae may be a site of weakness in tooth and form a road of entry for bacteria and initiate caries.

Indraprastha Dental College & Hospital
Principal
Sahibabad

- If discs are cut in an oblique plane near dentin in regions of cusps and incisal edges, the rod arrangement is more complicated.

- Enamel rods forming the developmental pits and fissure on occlussal surface of molars and premolars converging in their outer course.

Enamel spindles

- Before the ~~function~~ formatn of enamel certain odontoblastic processes project and get trapped b/w the adjacent ameloblast to form enamel spindles.

- They do not follow the directn of enamel rods.

- Spindles are more prominent in the cuspal region and generally oriented in a direction perpendicular to the DEJ.

Dental College & Hospital
Principal

Page No.
Date

Enamel lamellae

Enamel lamellae are thin, leaf like structures that extend from the enamel surface to the DEJ. Enamel lamellae extend for varying in depths from surface of enamel and consists of linear, longitudinally oriented defects filled with organic materials and little mineral content.

- It can be seen in transverse section.
- It can be seen in decalcified section because of protein content
- It is formed as a result of local failure of maturation process.

3 types

Type A: Lamellae composed of poorly calcified rod segments.
Type B: Lamellae consisting of degenerated cells.
Type C: Lamellae arising in erupted teeth where the cracks are filled with organic matter, preassuming originating saliva.

Indraprastha Dental College & Hospital * Sahibabad *

Page No.
Date

Enamel lamellae

Enamel lamellae are thin, leaf like structures that extend from the enamel surface to the DEJ. Enamel lamellae extend for varying in the depths from surface of enamel and consists of linear, longitudinally oriented defects filled with organic materials and little mineral content.

- It can be seen in transverse section.
- It is seen in decalcified section because of protein content.
- It is formed as a result of local failure of maturation process.

Types

- Type A: Lamellae composed of poorly calcified rod segments.
- Type B: Lamellae consisting of degenerated cells.
- Type C: Lamellae can be seen in erupted teeth where the cracks are filled with organic matter, presumming originating from saliva.

Inderprastha Dental College & Hospital * Sahibabad

[redacted]

classmate
Date
Page

Section – A

Q1- Enumerate the developmental disturbance affecting teeth. Discuss Amelogenesis Imperfecta in detail -(10)

→ Developmental disturbance of teeth are classified as –

(1) Size – Microdontia, Macrodontia

(2) Shape – Germination, fusion, concrescence, Dilaceration, Talson's cusp, Dens in dente (dens invagination, Dense Evaginatus, Taurodontium, supernumary tooth

(3) Eruption – Delayed Eruption, Eruption sequestrum, Embedded & impacted, Ankylosed

(4) Structure – Amelogenesis imperfecta, Dentinogenesis imperfecta, Regional odontodysplasia, Dentin dysplasia

⇒ Amelogenesis Imperfecta.

→ Amelogenesis Imperfecta is a heterogeneous group of hereditary disorders of Enamel formation, affecting both deciduous & the permanent dentition.

→ The disease involves only the ectodermal component of tooth i.e Enamel

→ dentin, cementum & pulp always remain normal.

⇒ Types

Normally, the process of Enamel formation progress through 3 stages.

(1) stage of Enamel matrix formation.
(2) stage of Early mineralization.
(3) stage of Enamel maturation.

Indraprastha Dental College & Hospital Principal Sahibabad

Amelogenesis Imperfecta may occur during any stage of Enamel formation.

→ Four basic types of the disease have been identified.

(I) Hypoplastic amelogenesis imperfecta
(II) Hypomaturation amelogenesis imperfecta
(III) Hypocalcification amelogenesis imperfecta
(IV) Hypomaturation - hypoplastic type with taurodontism

(I) Hypoplastic Amelogenesis Imperfecta

→ Enamel thickness is normal
- It defects the stage of matrix formation.
- The teeth exhibit either absence of enamel or a very min layer of enamel on crown surface.

(II) Hypomaturation type

- This type occurs due to defects in process of enamel matu
- Enamel thickness is normal.
- but doesn't have normal hardness & translucency (snow capped tooth)
- The enamel color is often yellow-white or yellow br--

(III) hypocalcification type

- It represents the disturbance in the process of early mineralization of the enamel.
- Enamel thickness is normal
- but enamel is soft & can be easily removed.

(IV) Hypo maturation - hypoplastic type with tauro-

- This is a rare condition where dentism. taurodontism is reported in association with Amelogenesis Imperfecta

Dental College & Hospital Principal

classmate
Date
Page

C/F- Amelogenesis Imperfecta affects both deciduous & permanent dentition
- Sex predilection varies according to mode of inheritance
- Colour of tooth is mostly chalky white but it can be yellow or even dark brown.
- teeth becomes sensitive and more prone to disintegra
- contact points in the proximal surfaces are mostly open either due to lack of formation or early loss of enam
- Occlusal & incisal edges surfaces are severely abrade
- Some time there is completely devoid of enamel, which result in severe dentin abrasion.
- Alteration in eruption pattern of teeth results in anterior open bite.
- pitted enamels, with many pitted grooves on surface of tooth
- teeth exhibits white opaque flecks at the incisal margins. These types of teeth known as snow-capped teeth.

R/F- The thickness and radiodensity of enamel varies greatly.
- The tooth may be completely devoid of enamel and where ever enamel is present.
- It is very thin and found in the tip of the cusps or interproximal areas.
- In hypoplastic type, the radiodensity of the enamel is usually greater than the adjacent dentin.
- The radiodensity of enamel in hypomaturation is almost equal to that of normal dentin.

Sahibabad Hospital

Histopathology.

- Enamel in hypoplastic type exhibits lack of differentia of Ameloblast cells with little or no matrix formation
- The Enamel in hypocalcification type shows defective matrix structure and abnormal mineral deposition.
- The hypomaturation type reveals alteration in the Enamel rod and rod sheath structures
- The dentin & pulp chamber appears normal.

Treatment.

→ There is no definitive treatment of amelogenesis imperfecta

→ Composite, veneering can be done to improve Esthetics

☆ Write Contents
☆ Elobrate the types
☆ Detailed Description about amelogenesis Imperfecta
☆ Diagrams
☆ Histopathological Eloberated
☆

Hindaprastha Dental College & Hospital Principal Sahibabad

Q2- define and classify "Cysts of the jaws". Describe calcifying odontogenic cyst. (10)

Definition- Cyst is a pathological cavity containing fluid, semifluid, or gas, which is usually lined by epithelium & is not formed by accumulation of pus.

→ Classification of cysts

Odontogenic

(1) Developmental

- gingival cyst of Infants
- odontogenic Keratocyst (primordial cyst)
- Dentigerous (follicular) cyst
- Eruption cyst
- Lateral periodontal cyst
- Gingival cyst of Adults
- Botryoid ~~cyst~~ odontogenic cyst
- Glandular odontogenic cyst
- Calcifying odontogenic cyst

(2) Inflammatory.

- Radicular cyst - apical & lateral
- Residual cyst
- Paradental cyst & mandibular infected buccal cyst
- Inflammatory collateral cyst.

(3) Non odontogenic cyst.

- Nasopalative duct cyst
- Nasolabial cyst
- Mid palatal raphe cyst of infants
- Medial palative, median alveolar, & median mandibular cyst
- Globulomaxillary cyst.

Sederpiastha Dental College & Hospital Principal Sahibabad

(3) Non Epithelial.
- Solitary bone cyst (traumatic, simple & hemorrhagic bone cyst)
- A neurysmal bone cyst

(4) Cyst Associated with Maxillary Antrum.
- Bering mucosal cyst of maxillary Antrum
- Post operative maxillary cyst

(5) Cyst of the tissues of the mouth, face, & neck.
- Dermoid & Epidermoid cysts
- Lymphoepithelial cyst
- Thyroglossal duct cyst
- Anterior median lingual cyst

⇒ Calcifying odontogenic cyst.
Also known as Gorlin cyst.
- This lesion is unusual in nature becz, It has some features of a cysts and many characteristics of solid neoplasm.

Classification Types of Calcifying odontogenic cyst.

- Typy 1 – Cystic
  Neoplastic
- Type II

- Type I – A – Simple unicystic type
- Type I – B – The odontome producing type
- Type I – C – The Ameloblastomatous proliferating types.

Type I – A.
C/F. occurs at any age
May be Intraosseous or Extraosseous.

Inderprastha Dental College & Hospital Principal Ghaziabad

classmate
Date
Page

- No sex or race predilection.
- Site - Anterior part of jaws.
- Extraosseous lesions - gingival or alveolar mucosa
- Anterior to 1st molar

Cp - Swelling, rarely painful
Some times perforate the cortical plates.
Displacement of teeth
Many times Asymptomatic

⇒ Histopathology
- Epithelium - low cuboidal or squamous (2-3 cells thick)
- focal areas of stellate reticulum & ghost cells.
- dentinoid is present
- No other mand tissue seen.

⇒ Ghost cells - Identify by gorlin
- Characterstically present in calcifying epithelium odontogenic cyst.
- pale eosinophillic swollen epithelial cells that have lots of nucleus, but show a faint outline of cellular & nuclear membrane
- They contain many tonofilaments
- A part from calcifying odontogenic cysts, also found in ameloblastic fibro-odontomatous complex & compound odontomatous

Indraprastha Dental College & Hospital
Principal
Sahibabad

Type I B.
C/F - predilection for occurence b/w 10-29 yrs of age.
Intraosseous or Extraosseous in location.
Site → clinical presentation same as Type IA.

Histopathology - unilocular cyst with similar type of lining to type IA
- In addition. Exhibits formation of calcified tissue in the cyst wall similar to those found in compound & complex odontomas.
- In the cyst wall proliferating tissue similar to ameloblastoma may be present which may invade the severe bone

Type I C
C/F - Mostly intraosseous.

Histopathology.
- cystic lesion
- Ameloblastoma like proliferation in the fibrous capsule as well as lumen of the cyst.

Type. II
C/F. Neoplasm like lesion.
occurs predominantly in later life.
intraosseous or Extraosseous.
Sometimes also called as "dentinogenic ghost cell tumor"
Histopathology.
- Ameloblastoma like strands & islands of odontogenic Epithelium.
infiltrating into mature connective tissue
- Ghost cells in varying number.
- varying amounts of dentinoid

R/F - Central lesions shows well circumscribed radiolucency
- usually with variable amounts of calcified radiopaque material scattered through out the radiolucency

Indira Gandhi Dental College & Hospital Jammu
Principal

- tiny flecks to large masses — depending upon the type.

Treatment and prognosis.

- Surgical excision.
- Recurrence is variable
- Occasional malignant transformation

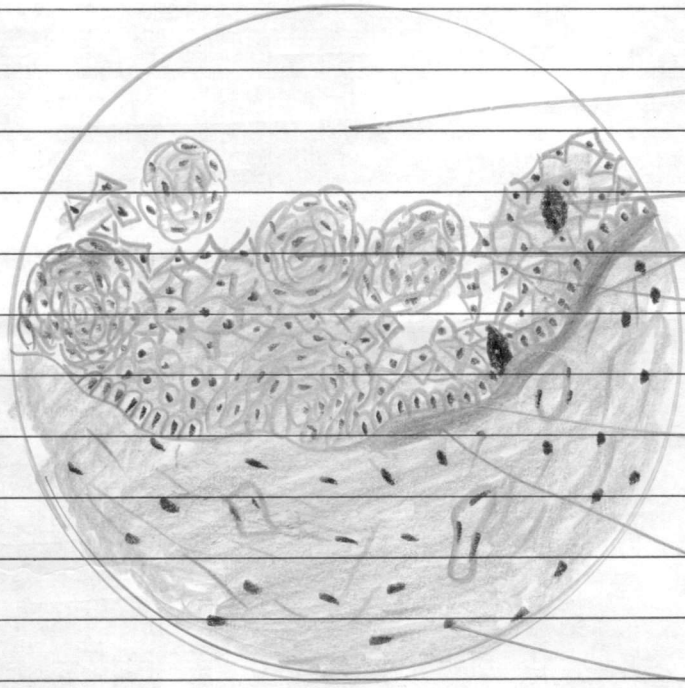

Calcifying odontogenic Cyst

☆ Write Contents

☆ H&E diagrams

☆ Ghost cells

Indraprastha Dental College & Hospital Sahibabad Principal

Inderprastha Dental College & Hospital

Remedial Classes

INDERPRASTHA DENTAL COLLEGE & HOSPITAL
46/1, Site IV Industrial Area, Sahibabad,
Ghaziabad (U.P.) - 201010, Delhi NCR

Department Of Oral Pathology & Microbiology

Remedial Classes

Batch: 2020 Year: 1st yr (P) 2021-22

Names of slow learners identified in the batch: Ayush, Kamal, Shivanji Singh, Gaurav Nath, Riya Nanda

S.no	Discussion/assignment/viva topic	Date	Staff
1.	Alveolar Bone with slides.	7/1/22	Dr. Kanika
2.	Oral Mucous membrane	10/1/22	Dr. Mayura
3.	Oral Mucous membrane with slides	14/1/22	Dr. Mayura
4.	Salivary glands with slides.	17/1/22	Dr. Gunjan
5.	Maxillary 1st molar	21/1/22	Dr. Mayura
6.	Mandibular 1st molar	24/1/22	Dr. Kanika
7.	Carving - maxillary 1st molar	28/1/22	Dr. Gunjan
8.	Carving - mandibular 1st molar	31/1/22	Dr. Gunjan
9.	Maxillary sinus with slides	4/2/22	Dr. Mayura
10	Revision test D.A	7/2/22	Dr. Kalyani
11	Revision test - D.H	11/2/22	Dr. Mayura

Inderprastha Dental College & Hospital Principal Sahibabad

Dept. of Oral Pathology & Microbiology Prof. & Head IPDC, SAHIBABAD

Retest- Date Sheet & Result

2nd Year

Inderprastha Dental College & Hospital

46/1, Site-IV, Industrial Area, Sahibabad,
Ghaziabad-201010 (U.P.)

2nd YEAR BDS (R)

RETEST DATE SHEET
2nd YEAR BDS (R)

DATE: 12.11.2022

Theory 9.00am-12.00pm

SL NO	DATE & DAY	SUBJECT
1.	21.11.2022 Monday	Pathology & Microbiology
2.	22.11.2022 Tuesday	Pharmacology
3.	23.11.2022 Wednesday	Dental Materials
3.	24.11.2022 Thursday	PCC
3.	25.11.2022 Friday	PCP

Note: Both Theory & Practical Exam will be conducted on the same day

Theory: 09.00 am -12.00pm

Practical: 12.30pm onwards

Inderprastha Dental College & Hospital Principal Sahibabad

Dr.Rahul Paul
(Principal)

DM - Re-test

Inderprastha Dental College & Hospital
46/1, Site-IV, Industrial Area, Sahibabad,
Ghaziabad-201010 (U.P.)

DEPARTMENT OF PROSTHODONTICS AND CROWN & BRIDGE

Department of Prosthodontics and Crown & Bridge
U.G Section

SECOND YEAR DM- IInd INTERNAL

S.NO	ROLL NO	NAME	MANUAL(10)	DENTAL CEMENT MANIPULATION (20)	VIVA(20)	TOTAL(50)
1.	206082007	Adeeba Khan	Absent	Absent	Absent	Absent
2.	206082038	Imran Siddiqui	7	10	10	27
3.	206082072	Riya Nanda	7	13	12	32

Inderprastha Dental College & Hospital * Sahibabad * Principal

Suprabha 28/11/22

Dept. of Prosthodontics And Crown & Bridge
U.G. Head
Dr. SUPRABHA RATHEE

(PCP) Re-test

INDERPRASTHA DENTAL COLLEGE AND HOSPITAL
46/1, SITE - IV , INDUSTRIAL AREA, SAHIBABAD
GHAZIABAD - 201010 (U.P.)

U.G. SECTION.

DEPARTMENT OF PROSTHODONTICS AND CROWN & BRIDGE

UG SECTION

SECOND YEAR PCP - IInd INTERNAL

S.NO	ROLL NO	NAME	MANUAL(20)	PCP EXERCISE ARTICULATION & CLASS I TEETH ARRANGEMENT(40)	VIVA(40)	TOTAL(100)
1	206082007	Adeeba Khan	Absent	Absent	Absent	Absent
2	206082038	Imran Siddiqui	5	10	15	30
3	206082072	Riya Nanda	5	15	15	35

Inderprastha Dental College & Hospital * Sahibabad * Principal

Suprabha 28/11/22

Dept. of Prosthodontics And Crown & Bridge
U.G. Head
Dr. SUPRABHA RATHEE

Inderprastha Dental College & Hospital
46/1, Site-Iv, Industrial Area, Sahibabad,
Ghaziabad-201010 (U.P.)

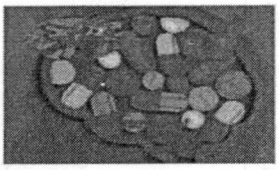

Department of General and Dental Pharmacology and Therapeutics

INTERNAL ASSESSMENT RETEST 22/11/22

S NO.	ROLL NO.	STUDENT NAME	THEORY (70)	VIVA (30)	PRACTICAL (100)
1.	206082007	Adeeba Khan	Absent	Absent	Absent
2.	206082038	Imran Siddiqui	36	17	56

Head Department Pharmacology
Inderprastha Dental College & Hospital
Sahibabad Ghaziabad

Inderprastha Dental College & Hospital
Principal
Sahibabad

Inderprastha Dental College & Hospital
46/1, Site-Iv, Industrial Area, Sahibabad, Ghaziabad-201010 (U.P.)
Department of General Pathology

Re-test

INTERNAL ASSESSMENT FORMAT

21.11.2022

S.NO	Roll NO.	Name	Theory (35)	VIVA (15)	Practical (50)
1.	206082007	Adeeba Khan	Absent	Absent	Absent

Principal
Inderprastha Dental College & Hospital
Sahibabad

Head, Department of General Pathology
Inderprastha Dental College & Hospital
Sahibabad, Ghaziabad (U.P.)

Inderprastha Dental College & Hospital
46/1, Site-Iv, Industrial Area, Sahibabad, Ghaziabad-201010 (U.P.)
Department of Microbiology

Microbiology

Retest

21.11.2022

INTERNAL ASSESSMENT FORMAT

S.NO	Roll NO.	Name	Theory (35)	VIVA (15)	Practical (50)
1.	206082007	Adeeba Khan	Absent	Absent	Absent

Inderprastha Dental College & Hospital * Sahibabad * Principal

SK

Head, Department of Microbiology
Inderprastha Dental College & Hospital
Sahibabad, Ghaziabad (U.P.)

Inderprastha Dental College & Hospital
46/1, Site-IV, Industrial Area, Sahibabad,
Ghaziabad-201010 (U.P.)

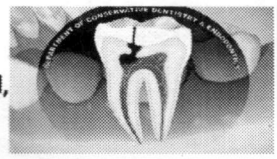

Department of Conservative Dentistry & Endodontics

U.G .Section

Retest

Retest. II. **INTERNAL ASSESSMENT FORMAT IInd Year Date:** 24/11/22

S.No.	Name	Spotting (20)	Cavity (30)	Base (10)	Restoration (20)	Viva (20)	Total (100)
1	Adeeba Khan	Absent	Absent	Absent	Absent	Absent	Absent

Inderprastha Dental College Hospital Sahibabad

CONSERVATIVE DENTISTRY & ENDODONTICS IDDC

Retest- Date Sheet & Result

3rd Year

Inderprastha Dental College & Hospital

46/1, Site-IV, Industrial Area, Sahibabad,
Ghaziabad-201010 (U.P.)

RETEST DATE SHEET
3rd YEAR BDS (R)

DATE: 12.11.2022

THEORY 9.00AM-12.00PM

SL NO	DATE & DAY	SUBJECT
1.	21.11.2022 Monday	GENERAL MEDICINE
2.	22.11.2022	GENERAL SURGERY
3.	23.11.2022 Wednesday	ORAL PATHOLOGY

Note: Both Theory & Practical Exam will be conducted on the same day

Theory: 09.00 am -12.00pm

Practical: 12.30pm onwards

Inderprastha Dental College & Hospital Principal Sahibabad

Dr.Rahul Paul
(Principal)

Inderprastha Dental College & Hospital
46/1, Site-IV, Industrial Area, Sahibabad,
Ghaziabad-201010 (U.P.)

Department of Oral Pathology & Microbiology

25/11/22

INTERNAL ASSESSMENT FORMAT– Retest

S.NO	Roll NO.	Name	Theory (70)	VIVA (30)	Practical (100)
1.	196081004	Abhinav Akash	35	18	53
2.	196081062	Rishita Bareja	31	17	57
3.	196081053	Priya Anand D	25	07	29
4.	196081087	Tejaswini Pandey	39	17	50

Inderprastha Dental College & Hospital * Sahibabad * Principal

Dept. of Oral Pathology & Microbiology * IPDC, SAHIBABAD * Prof. & Head

Inderprastha Dental College & Hospital
46/1, Site-Iv, Industrial Area, Sahibabad,
Ghaziabad-201010 (U.P.)
Department of General Surgery

INTERNAL ASSESSMENT FORMAT-Retest 24/11/22

S.NO	Roll No.	Name	Theory (70)	Viva (30)	Practical (100)
1	196081004	Abhinav Akash	32	17	52
2.	196081053	Priya Awana D	34	16	55

Department of General Surgery Prof. & Head

Inderprastha Dental College & Hospital Principal Sahibabad

Inderprastha Dental College & Hospital
46/1, Site-Iv, Industrial Area, Sahibabad,
Ghaziabad-201010 (U.P.)
Department of General Medicine

INTERNAL ASSESSMENT FORMAT-Retest 23/11/22

S.NO	Roll No.	Name	Theory (70)	Viva (30)	Practical (100)
1	19608 1004	Abhinav Akash	30	18	50
2.	196081086	Tanishqua Mathura	33	16	55

Department of General Medicine
Prof. & Head

Principal
Inderprastha Dental College & Hospital
Sahibabad